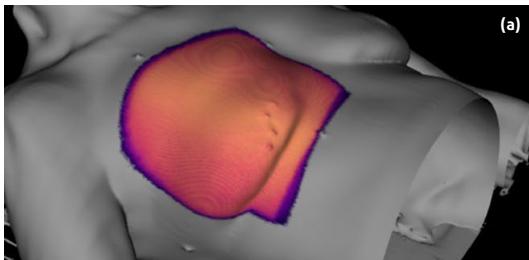


# Unintended radiation dose to contralateral breast identified by Cherenkov Imaging <sup>1</sup>

**PATIENT:** Patient with limited arm mobility receives standard whole breast radiation. Due to previous injury, the patient was unable to raise her arm above her head, consequently, her arm is positioned down.

**METHODS:** SGRT using AlignRT was used in patient set-up for every fraction and was within tolerance before start of each treatment. Patient was treated with 16 fractions, of which a total of 8 were imaged with BeamSite.



**SUMMARY:** The first panel (a) shows the treatment as planned, rendered from the CT and planning software showing the expected location of surface dose. Panels (b, d, f) show images taken during tangential beam delivery of separate fractions.

Figure a – 3D body rendering: CT scan  
Treatment field: TPS

DAY	IMAGE
05/30	
06/03	
06/06	

Panels (b), (d), and (f) show treatment days when an otherwise undetectable change in the patient positioning resulted in dose to the contralateral breast (b and d, arrows) or ipsilateral arm (f, arrow).

**KEY LEARNINGS:** This patient represents a difficult treatment case where, due to mobility issues, there exists a tight tolerance on positional accuracy. Cherenkov imaging with BeamSite shows evidence of the exposure consequences under these conditions. For similar cases in the future, the ROI of AlignRT could be increased or immobilization devices could be employed to improve the set up accuracy.